

Automated Detection and Classification of Liver Cancer from CT Images using HOG-SVM model

Zarif Al Sadeque¹
Electrical and Electronic
Engineering
Chittagong University of
Engineering & Technology
Chittagong-4349, Bangladesh
zarif.sadeque11@gmail.com

Tanvirul Islam Khan²
Electrical and Electronic
Engineering
Chittagong University of
Engineering & Technology
Chittagong-4349, Bangladesh
tanvirriyad12@gmail.com

Quazi Delwar Hossain³
Electrical and Electronic
Engineering
Chittagong University of
Engineering & Technology
Chittagong-4349, Bangladesh
quazi@cuet.ac.bd

Mahbuba Yesmin Turaba⁴
Information and Communication
Technology
Comilla University
Cumilla-3506, Bangladesh
mahbuba.yesmin11@gmail.com

Abstract— Liver cancer patients have a high death rate due to the diagnosis of the disease in the final stages. Computer-aided diagnosis from various medical imaging techniques can assist significantly in detecting liver cancer at a very early stage. This paper presents an automated method of detecting liver cancer in abdominal CT images and classifying them using the histogram of oriented gradient - support vector machine (HOG-SVM) algorithm. The proposed model consists of several stages where the image is first normalized and preprocessed using a Median and Gaussian filter to remove noise in the image. The image segmentation and liver area extraction are executed in the second stage combining thresholding and contouring. We integrated an ROI based histogram oriented gradient (HOG) feature extraction to train the classifier which impels the classification faster than the conventional methods. Finally, liver CT images are classified implementing support vector machine and segmented results are highlighted with different markers. The proposed system is tested on real data of 27 confirmed early-stage liver cancer and the experimental result shows an accuracy of 94% detecting liver cancer.

Keywords— *Computed Tomography (CT), Liver Cancer, Image segmentation, Classification, SVM, Feature Extraction, Histogram oriented gradients (HOG)*

I. INTRODUCTION

Liver cancer is the world's sixth most common cancer and it is more found in male than female according to world cancer research fund (WCRF) [1]. It is the second most dominant cancer for death and every year at least 550,000 people die from liver cancer all around the world [2]. Liver cancer or primary liver cancer is that cancer which emanates from the liver. The most lethal and commonly found primary cancer is Hepatocellular carcinoma (HCC) in the liver which is basically a malignant tumor. Cancer originating from a different part of the body and further spread into the liver is commonly known as Metastases or secondary liver cancer. It is critical to annihilate liver cancer if it is diagnosed at a late stage. Therefore it has been under extensive priority to detect this cancer in an early stage.

In recent years medical image processing has become an essential part of diagnosing and accumulating disease information for aiding in clinical decision support. It is also helpful for monitoring and examining the impact of treatment on infected cells. For liver cancer detection, multiple imaging methods are used including Ultrasound, Magnetic Resonance Imaging (MRI) and Computed tomography (CT). CT scan is one of the key imaging processes for liver cancer identification which is popular being non-invasive, high resolution and precision of cancer tumor localization. Thus, it has been subjected to substantial attention for cancer research. Doctors usually undergo many tests for the confirmation of cancer and unusual cell growth inside the liver. Sometimes the test report takes time to be overviewed by the specialists and all these observations are manual. Besides, the spatial morphological transformations are not very significant at the early stage of liver cancer or malignant tumor [3]. Hence, it becomes more strenuous for diagnosis or even wrong diagnosis in some cases.

In the modalities of diagnosing liver cancer or malignant tumor, segmentation and quantitative analysis is a major part. Several studies on automatic/semiautomatic methods for liver tumor detection and segmentation have been inaugurated depending on strategies including Bayesian approaches, entropy-based segmentations, Level-set techniques, multi-level thresholds, and region growing techniques [4]. From previous case studies, it has been found that supervised classification models have better performance in accuracy and more effective for segmenting liver cancer. In this paper, we have approached to design a novel system for automated detection of liver cancer from the CT scan images which will save up time for doctors as well as assist them to oversee the treatment effect on cancer cells.

II. RELATED WORK

For liver cancer or malignant tumor diagnosis, several studies have been developed using multiple algorithms and feature extraction method along with different classifiers. A completely automatic system for segmenting liver tumors without human interaction has been proposed by Abdel-Massieh et al. [5]. In this process, they have used thresholding

method on segmented liver on a binary image to separate the liver tumor. Zhang and his peers have presented an interactive method where the CT volume has been partitioned into many catchment basins by watershed transform and trained the Support vector machine classifier from user-selected seed points to segment the liver tumor [6].

A texture-based classification model has been introduced by Huiyan Jiang, Fengzhen Tang, and Xiyue Zhang. After selecting the ROI by Lazy-Snapping and extracting texture features they used F-score algorithm to select relevant features [7]. They feed these data to train their model to classify liver cancer combining parallel Support Vector Machine with Particle Swarm Optimization method from CT image. Wen-Jia Kuo also brought another model using the PSO-SVM algorithm where he used the statistical feature matrix for primary texture feature extraction which procured an accuracy of 80% on both benign and malignant tumors recognition [8].

In our algorithm, we incorporated the histogram oriented gradient feature which has been previously used for traffic sign detection, car or other vehicle recognition, pedestrian tracking and also in other image segmentation algorithms. Yao Chang along with his co-researchers presented a method for detecting traffic signs using HOG features and integrated grid search to optimize for classification using SVM [9].

III. MATERIALS AND METHOD

In our research, a computer-based image processing technique with Open Source Computer Vision (OpenCV) integrated with python language has been used. The information from the CT scan is recorded in the format of DICOM images (Digital imaging and communications in medicine). The collected data can be represented as a 2D image slice or 3D volume reconstructed from a set of 2D images.

During this research, a number of dummy images are taken from The Cancer Imaging Archive (TCIA) and the other real-time liver cancer images are convened from CHEVRON diagnostic center. Here all the training and test dataset that was pre-diagnosed with cancer have been confirmed and localized in the image by cancer specialists from Mohakhali Cancer Institute. The images, therefore, prepared for analysis using a medical image conversion tool, radiant DICOM viewer. The DICOM files exchange between the two entities that are capable of receiving an image and patient data in its own format, following the interconnection and the interaction of the equipment and transfer the data [10]. The images thus can be transformed from the DICOM images to any regular image format. For our work and also in any image processing domain for medical purposes, it is compelling to use the ‘.BMP’ as image format which is accessible for further image processing. For writing, debugging and testing of the program an IDE called ‘Anaconda’ has been used. In this research, the liver cancer segmentation is proposed based on intensity distribution in the ROI with a unique algorithm combining support vector machines and adaptive thresholding process.

The proposed CAD model (Fig.1) in this paper encompasses three major stages, including (A) image preprocessing, (B) defining the region of interest (ROI), (C) feature vector extraction using Histogram Oriented Gradients,

followed by (D) Model training and (E) Cancer Detection & Classification.

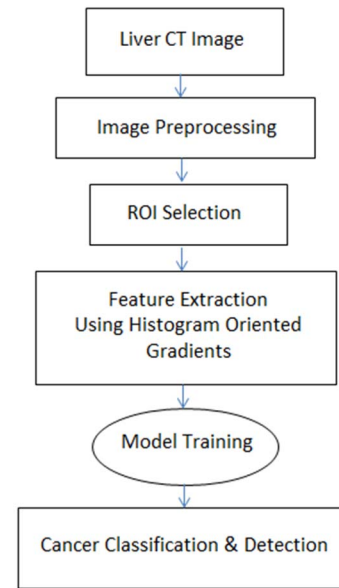


Fig. 1. The complete diagram of the proposed model for liver cancer detection & Classification

A. Image Preprocessing

For the training phase, we have selected a total of 100 confirmed HCC images along with 100 normal state liver CT image. Each input image is a color image containing 512×512 pixels. This first stage image preprocessing is carried through a Gaussian filter of 1×1 window followed by a Median filter with a kernel size of 3×3 window as shown in the fig. 2. We label this image as the base image (Ibase) for ROI selection. The Gaussian filter helps to remove the random noise from the image before other filtering or segmentation process comes into action. Thus the computational complexity also gets reduced for the whole model. On the other hand, the leverage of using a Median filter is that it doesn't generate any unusual pixel values while the window undergoes an edge inside the image. Hence the data all over the image persists almost intact. CT images get corrupted by unwanted and random noise in the process of data transmission and digitization during image compression.

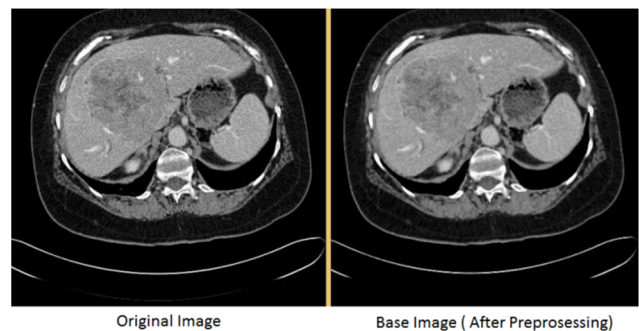


Fig. 2. Before and after image preprocessing with gaussian & median filter

B. ROI Selection

This second stage of our model is executed in three sub-stages comprising, (i) Liver Preprocessing, (ii) Liver Boundary Segmentation (iii) Final ROI selection

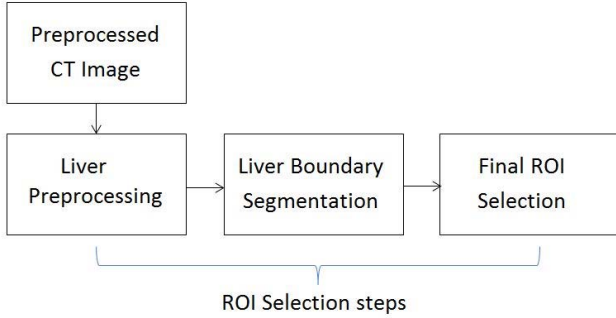


Fig. 3. Three steps ROI Selection for feature extraction

(i) *Liver Preprocessing*: We used the base image $I_{base}(h,v)$ as the input image for the liver preprocessing. The primary task of this operation is to filter out the unwanted dark and bright portions in the CT image and therefore providing a clear path to extract the liver. An 11×11 window of Median filter along with Gaussian filter of 9×9 window size is applied to allow merging the neighboring pixels in the spatial domain of the resulting image $I(h,v)$ with a close gray-level intensity inside the liver region. After that, a binary threshold image $t(h,v)$ is constructed using the threshold technique where the limits are calculated using the mean filter with a suitable constant. The constant is positive for the upper limit and negative for the opposite. The threshold function is processed implementing the following equation.

$$t(h,v) = \begin{cases} 1 & \text{if } I(h,v) > \text{mean} + C1 \\ 0 & \text{if } I(h,v) < \text{mean} - C2 \end{cases} \quad (1)$$

This sub-stage eliminates mostly the portions outside the cross-section of the chest boundary and the spinal region. To obtain the primary region of interest we endorsed the contour with the largest area from the threshold image as a binary mask $M(h,v)$ by means of only the external border for each contour. The function is operated with a simple chain approximation which reduces the number of points to define the contour saving memory and computation time. Then we used the image mask $M(h,v)$ with the base image $I_{base}(h,v)$ as a bitwise AND operation which multiplies every pixel from the base image with the corresponding pixel from the mask of the same position in the image array.

$$I_{LP}(h,v) = I_{base}(h,v) * M(h,v) \quad (2)$$

The whole liver preprocessing algorithm can be depicted as fig. 4.

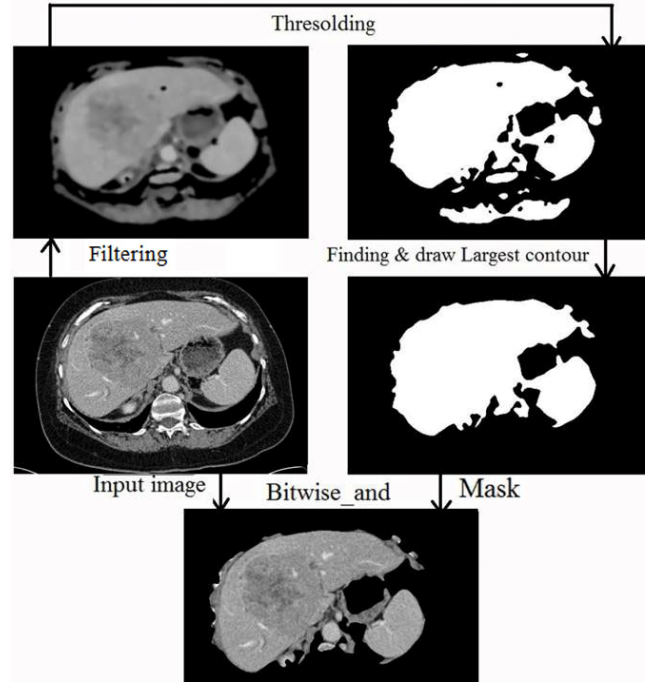


Fig. 4. Liver Preprocessing (Input image, Filtering, Drawing contour, Masking, final preprocessed liver image)

(ii) *Liver Boundary Segmentation*: Subsequently defining the primary region of interest, in this sub-stage the liver is segregated using the same technique. Instead of using a smaller window size the kernel was 37×37 for the median filter and 21×21 for the Gaussian window size. The larger window size of the Median and Gaussian filter squeezes down the edges which help to reduce the error in detecting the edges of the liver. For the threshold function this time no constant was used for the lower limit along with the mean value. The equation for threshold function is constituted as

$$t(h,v) = \begin{cases} 1 & \text{if } I(h,v) > \text{Mean} + C3 \\ 0 & \text{if } I(h,v) < \text{Mean} \end{cases} \quad (3)$$

It is also experimented to combine the two sub-stages of liver preprocessing and liver segmentation in a single stage. But implying various windows sizes in the first sub-stage it has found that a larger window size than 11×11 for median filter and 9×9 for Gaussian filter tends to reduce the performance for the segmentation of liver. Accordingly, a smaller window provides less homogeneity in gray level intensity between the pixels inside the liver which also reduces the segmentation performance. The rest of the process is followed by creating a mask using the largest contour and multiplying it with the Preprocessed liver image $I_{LP}(h,v)$ to approximate the final extracted liver $I_L(h,v)$ as fig. 5.

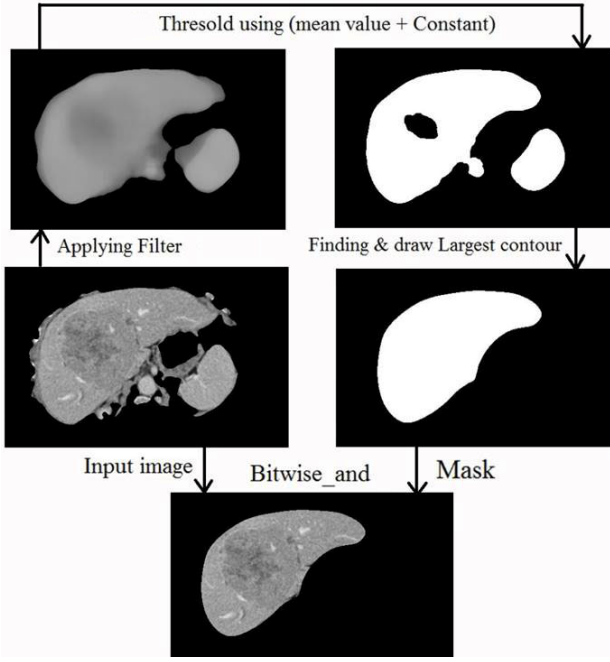


Fig. 5. Liver boundary segmentation (Preprocessed liver image, Filtering, Drawing contour, Masking, final segmented liver image)

(iii) *Final ROI selection*: A primary mask has been used to remove the bright spots referring to blood vessels inside the liver CT image which might diversify the features in the next step. The rest of the procedure is similar to the liver segmentation method. To get a better output, the probable cancer regions are primarily thresholded from the filtered liver image $I(h,v)$ involving the mean value and a constant to create the mask. Although, for the AND operation, the segmented liver image $I_L(h,v)$ was used with the mask which preserves more spatial information in order to extract the HOG features for the following stage.

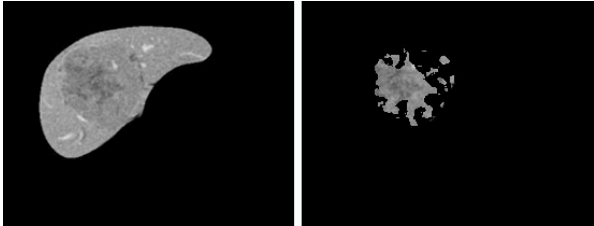


Fig. 6. Final ROI selection from the segmented liver image

C. Feature extraction using the Histogram oriented Gradients

Features are elucidated as a vector, composed of only essential attributes of an image. In our case, we utilized the Histogram Oriented Gradients as the feature vector to train the classifier. At first, we calculated the magnitude and the orientation of the gradients at each pixel of the final spatial region of interest in the image. The gradient computation can be done using a variety of masks of 1D point derivatives [11]. The easiest way to compute the gradients is using a simple kernel of $[-1,0,1]$ which also results in better performance than any larger kernel such as diagonal or cubic corrected masks.

The magnitude and the angle is calculated as of the following equations.

$$G = \sqrt{G_h^2 + G_v^2} \quad (4)$$

$$\Theta = \arctan \frac{G_h}{G_v} \quad (5)$$

The HOG descriptor splits the image into smaller cells defined by the number of pixels by the user. We have used a cell size of 16×16 pixels which accumulates a total of 256 magnitudes and 256 orientations. The next step of Histogram calculation is spatial binning of the gradients according to their orientations which forms the channels in the histogram. We validated 9 orientation bins that divide the orientation evenly at every 20° over 0° to 180° . These are unsigned orientations since a gradient and the negative of that are considered the same for binning. The votes are aggregated for every pixel in the cell according to the direction of the gradients and weighted by their magnitude. Any individual gradient might corrupt by noise therefore; histogram computed by spatial binning of the gradients makes it less exposed to noise. To make the HOG representation more robust and less sensitive to exposure variations we incorporated the L2 normalization over a block size of 2×2 cells which divides the image into 16 sub-squares. The normalized HOG features are calculated over each block separately which produces a 9×1 element vector from 9 orientations. From 16 sub-squares or blocks, the final feature vector forms a vector of $16 \times 9 \times 1$, therefore a vector of 144×1 elements.

D. Model Training

The feature vector from every training image is labeled as positive and negative and appended into the SVM classifier. SVM is a supervised machine learning algorithm that maps the data set in a feature space and classifies them as a binary classifier. The procedure of support vector machine works by finding the decision boundary or the hyperplane which implies the largest minimum margin from the training dataset. If our training examples are,

$$(x_i, y_i) = (x_1, y_1) (x_2, y_2) \dots (x_n, y_n) \quad (6)$$

Where,

x_i = Feature vector for each training sample

$$y_i = \text{Training label} \begin{cases} 1 & \text{if sample is cancerous} \\ -1 & \text{if sample is not cancerous} \end{cases} \quad (7)$$

We can simply find the hyperplane solving the following optimization problem such that,

$$y_i * (w * x_i + b) \geq \gamma \quad (8)$$

Where,

γ = Minimum Margin
 w = Weight Vector

The equation for the optimal hyperplane can be written as,

$$w*x_i + b=0 \quad (9)$$

The optimization problem for linearly inseparable classes can be solved by kernel trick using linear, polynomial or RBF kernels. In our research approach, we have used the SVM with the linear kernel which can compute faster with good accuracy.

To evaluate the stability of the proposed algorithm and avoid overfitting, it has been validated with K-Fold Cross Validation method with a fold number of 5. We used the scikit library with python to determine the cross-validation score. The score is found 0.95 which indicates the proposed algorithm is stable.

E. Cancer Detection & Classification

The test phase extracts the feature vector from the test image and predicts simply using the sign of the distance from the optimal hyperplane to the feature vector.

$$\text{Prediction} = \text{sign}(w*x_i + b) \quad (10)$$

If the prediction is a positive class the test image is classified as Cancer Affected and thus the detected region is marked with red and yellow marker according to the gray level intensity as shown in fig. 7

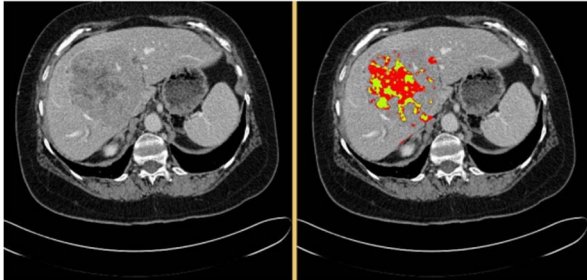


Fig. 7. Cancer Detection & Classification

IV. EXPERIMENTAL RESULTS AND ANALYSIS

The research model has experimented on 50 Liver CT image including 27 confirmed with Liver Cancer. In order to estimate the performance of our proposed model, the confusion matrix is employed with two variations of ROI and

utilization of the block normalization in the feature vector. We have measured the following parameters to determine the performance.

$$\text{Accuracy (\%)} = \frac{TP+TN}{TP+FN+TN+FP} \times 100 \quad (11)$$

$$\text{True Positive Rate (\%)} = \frac{TP}{TP+FN} \times 100 \quad (12)$$

$$\text{True Negative Rate (\%)} = \frac{TN}{TN+FP} \times 100 \quad (13)$$

The feature vectors from same dataset are tested with two machine learning methods (HOG-SVM and KNN). The experimental results of different measures are shown in Table 1. The HOG-SVM model performed better with L2 normalization on our test dataset with 94% accuracy. However with same feature vector with L2 norm KNN achieved only 86%. To assess the quality of the proposed model a relative study is delineated in Table-2 with proclaimed literature of some conventional methods. As per the measure of accuracy we can determine the proposed model has better performance classifying the HCC or malignant tumor. The proposed model also found better segmenting the liver boundary with fuzzy borders and accurate localizing the HCC.

TABLE I. PERFORMANCE EVALUATION

Model	Variations	Accuracy(%)	TPR(%)	TNR(%)
HOG-SVM	Primary ROI With L2 Norm.	90.00	88.888	91.304
	Primary ROI Without Norm.	88.000	85.185	91.304
	Final ROI Without Norm.	92.00	88.888	95.652
	Final ROI With L2 Norm. (Proposed)	94.00	92.592	95.652
KNN	Final ROI With L2 Norm	86.00	88.462	80.00

CONCLUSION

In this research study, we presented an automated method of classifying the Liver CT image with Liver cancer or

TABLE II. COMPARISON WITH SOME CONVENTIONAL MODELS

Author/Year	Input Method	Classes	Model Used	Accuracy (%)
Proposed Method	CT	HCC & malignant	Hog-SVM	94
Chang et al. (2017) [12]	CT	Benign, malignant	Combined GLCM. Shape & kinetic curve	81.82
Alahmer et al. (2016) [13]	CT	Benign, malignant	Multiple ROI based SVM	89
Selavati et al. (2014) [14]	MRI	Liver cancer, benign type liver	Histogram based SVM	86.67
Mittal et al. (2011) [15]	Ultrasound Image	Cyst, Hemangioma, HCC	Texture	86.4

malignant tumor. Our proposed algorithm is novel in terms of segmenting the liver boundary and ROI based approach with HOG-SVM model on CT image. Segmenting the cancer region is a difficult and burdensome task as we have to correspond with structures of high irregularity with a huge amount of noise. In addition, the structures also vary in accordance with complex texture changes. Therefore, our proposed system is robust in terms of segmenting and able to apprehend complexity with highly variable features. According to the performance evaluation from the testing dataset, our proposed model achieves a classification accuracy of 94%. Also, a linear SVM requires less computation but exhibits a very good accuracy within this approach. We have also integrated the proposed CAD model with a GUI to operate with any clinical assist system which is also examined by experienced doctors and highly appreciated. Better accuracy and robustness could be achieved if more training samples were provided to train the classifier. We would like to research further with other segmentation methods combining with different classifiers and feature variations.

ACKNOWLEDGMENT

We would like to thank Mr. Ainul Anam Md. Shahjamal khan (Associate Professor of Department of Electrical & Electronic Engineering, Chittagong University of Engineering and Technology, Bangladesh) and Mr. Pradipta Saha for their valuable advice and suggestions throughout the project. We are also grateful to CHEVRON Diagnostic Center, Chittagong, Bangladesh for providing useful data and co-operation in the research.

REFERENCES

[1] <https://www.wcrf.org/dietandcancer/liver-cancer>. (28/04/2019)
 [2] Liver Cancer Information <https://www.disabled-world.com/health/cancer/liver>. (31/04/2019)
 [3] Songnian Li. "Modern Whole Body CT Diagnosis" [M]. China Medical Science and Technology Press, 2013, 35(6).

[4] Rajagopal, R & Subbaiah, P. (2015). A survey on liver tumor detection and segmentation methods. *ARPN Journal of Engineering and Applied Sciences*. 10. 2681-2685.
 [5] Abdel-Massieh, N. H., Hadhoud, M. M., and Amin, K. M., "Fully automatic liver tumor segmentation from abdominal CT scans," *IEEE International Conference on Computer Engineering and Systems (ICCES)*, pp. 197–202, 2010
 [6] Zhang, X., Tian, J., Xiang, D., Li, X., and Deng, K., "Interactive liver tumor segmentation from ct scans using support vector classification with watershed," *IEEE Conf. Eng Med Biol Soc.*, vol. 2011, pp. 6005–6008, 2011.
 [7] Jiang, Huiyan & Tang, Fengzhen & Zhang, Xiyue. (2010). Liver cancer identification based on PSO-SVM model. 2519-2523. 10.1109/ICARCV.2010.5707396.
 [8] Kuo, Wen-Jia. (2018). Computer-aided diagnosis for feature selection and classification of liver tumors in computed tomography images. 1207-1210. 10.1109/ICASI.2018.8394505.
 [9] Yao, Chang & Wu, Feng & Chen, H-J & Hao, X.-L & Shen, Yan. (2015). Traffic sign recognition using HOG-SVM and grid search. *International Conference on Signal Processing Proceedings, ICSP. 2015*. 962-965. 10.1109/ICOSP.2014.7015147.
 [10] Kumar, S. S., Moni, R. S. (2010). Diagnosis of liver tumor from CT images using curvelet transform. *International Journal of Computer Science and Engineering*, 2(4), 1173-1178.
 [11] Dalal, Navneet & Triggs, Bill. (2005). Histograms of Oriented Gradients for Human Detection. *IEEE Conference on Computer Vision and Pattern Recognition (CVPR 2005)*.
 [12] Chang CC, Chen HH, Chang YC, Yang MY, Lo CM, Ko WC, Lee YF, Liu KL, Chang RF, Computer-aided diagnosis of liver tumors on computed tomography images, *Comput Methods Programs Biomed*145:45–51, 2017.
 [13] Alahmera H, Ahmed A, Computer-aided classification of liver lesions from CT images based on multiple ROI, *Procedia Comput Sci*90:80–86, 2016.
 [14] Selvathi D, Malini C, Shanmugavalli P, Automatic segmentation and classification of liver tumor in CT images using adaptive hybrid technique and contourlet based ELM classifier, *Int Conf Recent Trends Inf Technol*, Chennai, India, pp. 205–256, 2013.
 [15] Mittal V, Kumar SC, Saxena N, Khandelwal D, Kalra N, Neural network based focal liver lesion diagnosis using ultrasound images, *Comput Med Imaging Graph*35:315–323, 2011.